

CASE REPORT

Open Access



Unusual occurrence of orbital hemangiopericytoma in the zygomatic bone of an adolescent: a case report

Bahram Eshraghi, Hadi Ghadimi* and Zohreh Nozarian

Abstract

Background: Hemangiopericytoma and solitary fibrous tumor are considered related variants on the same spectrum and both may essentially be the same tumor. They are infrequently encountered in the orbital region while the zygomatic bone is an extremely rare location for these neoplasms to occur.

Case presentation: A 14-year-old boy presented with complaint of deformity of left infraorbital area and a firm, regular mass in the region. Orbital CT scan revealed a well-defined round isodense intraosseous lesion in the lowermost portion of the lateral orbital wall (zygomatic bone), expanding the bone and protruding anteriorly and medially. MRI showed the mass to be heterogenous and strongly enhancing with contrast medium. Inferior transconjunctival orbitotomy was performed and the mass was removed. The histopathologic examination and immunohistochemistry staining results (positive for CD34, CD31 and smooth muscle actin, but negative for CD99, S100, B-cell lymphoma 2 (bcl-2) and desmin) confirmed the diagnosis of hemangiopericytoma. The postoperative course was uneventful, with no evidence of recurrence after 5 years follow up.

Conclusions: This case represents the second hemangiopericytoma reported in the zygomatic bone. Although extremely rare, hemangiopericytoma/solitary fibrous tumor might be considered in the differential diagnosis of intraosseous lesions of the orbital and zygomatic region.

Keywords: Hemangiopericytoma, Orbital neoplasm, Solitary fibrous tumor, Zygomatic bone

Background

Vascular tumors of the bone are uncommon, accounting for 1–2% of bone tumors [1]. Hemangiopericytoma (HPC) is an infrequent vascular neoplasm that has a propensity for soft tissues and rarely involves bony skeleton [2], constituting 4.7% of primary vascular bone tumors [3]. Occurrence of hemangiopericytoma in the zygomatic bone is extremely rare, with only one previous report in the literature [4]. We present an adolescent with HPC of zygoma who underwent successful surgical treatment.

Case presentation

A 14-year-old boy was referred with complaint of deformity of left infraorbital region. There was fullness in the inferolateral orbital and periorbital areas (Fig. 1) and a firm, regular mass was palpable in the region. The patient had felt the bulging for almost a year. No limitation of ocular motility was observed, but lateral canthus was slightly displaced superiorly compared to the other side. The mass was neither painful nor tender and the overlying skin appeared normal. Past history was unremarkable and the patient denied history of any trauma.

Orbital CT scan revealed a well-defined round isodense intraosseous lesion in the lowermost portion of the lateral orbital wall, expanding the bone and protruding anteriorly and medially (Fig. 2a and b). MRI showed the mass to be heterogenous and strongly enhancing with contrast medium (Fig. 2c and d). Based on available information, the clinical suspicion of a vascular lesion

* Correspondence: hadi.ghadimi@gmail.com

Eye Research Center, Farabi Eye Hospital, Tehran University of Medical Sciences, Qazvin Sq, Tehran 1336616351, Iran



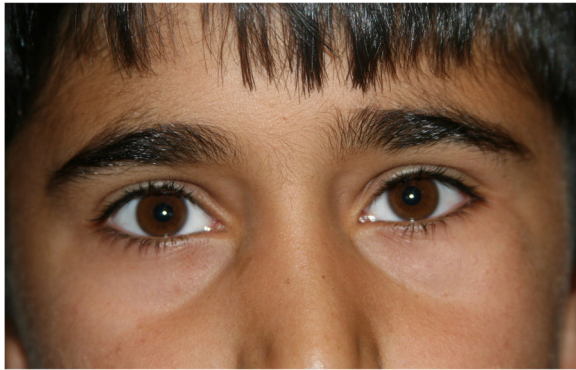

Fig. 1 Preoperative facial photograph. Frontal view of the patient before operation, showing fullness of left inferolateral orbital and periorbital region with slightly upward displacement of the lateral canthus

was aroused. Under general anesthesia, inferior transconjunctival orbitotomy was performed and the mass was exposed. The bony roof of the lesion was removed, piecemeal excision of its contents was carried out by curettage and hemostasis was achieved with the aid of Surgicel (Ethicon, Somerville, NJ). Intralesional triamcinolone acetonide was injected at the termination of surgery before suture closure of the conjunctiva.

Histopathologic examination revealed the mass to be composed of several slit-like vascular channels, with occasional stag-horn appearing vessels, surrounded by elongated bland-looking spindle cells (Fig. 3a and b). Occasional mitotic figures (1 per 20 high power fields)

were seen. As the specimen was received as fragmented pieces, exact evaluation of surgical margins was not possible. However, in some of the larger pieces evaluated, surrounding soft tissue and margins showed no tumor involvement. Immunohistochemistry (IHC) staining results were positive for CD34 and CD31 in endothelial cells (Fig. 3c) and for smooth muscle actin (SMA) in spindle cells (Fig. 3d), but negative for CD99, S100, B-cell lymphoma 2 (bcl-2) and desmin, suggesting the presence of HPC. The postoperative course was uneventful, with the patient doing well without clinical or radiologic signs of recurrence after 5 years follow up (Figs. 4 and 5a, b).

Discussion and conclusions

HPC is a rare vascular soft-tissue tumor that can develop anywhere in the body that has blood vessels, most notably in lower extremities, pelvic fossa, retroperitoneum and nasopharynx [5]. HPC rarely involves the orbit [6] and constitutes only 1.57% of orbital tumors [7]. Likewise, bones are uncommonly involved in HPC, which accounts for 4.7% of bone tumors [2, 3]. Zygomatic bone involvement by intraosseous malformations is rare and HPC of the zygoma has only been reported once [4]. This case represents the second reported instance of intraosseous HPC of the zygoma. In the case reported by Asrani et al. [4], a diagnosis of HPC of the zygoma was made although IHC results were not presented, and the patient was followed for 2.5 years after surgery.

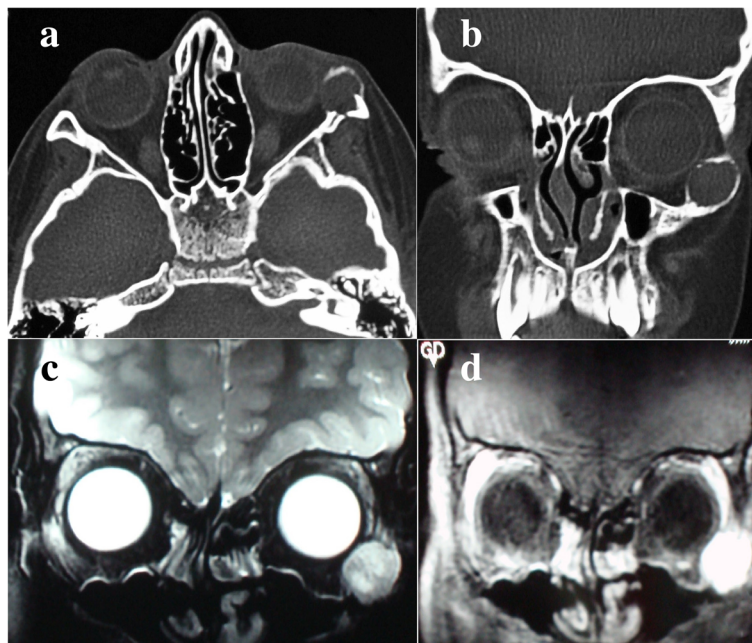


Fig. 2 Preoperative imaging. CT scan reveals an isodense intraosseous lesion in the zygomatic bone in axial (a) and coronal sections (b). In orbital MRI, the mass appears heterogenous in T2-weighted images (c) and shows remarkable contrast enhancement after gadolinium injection (d)

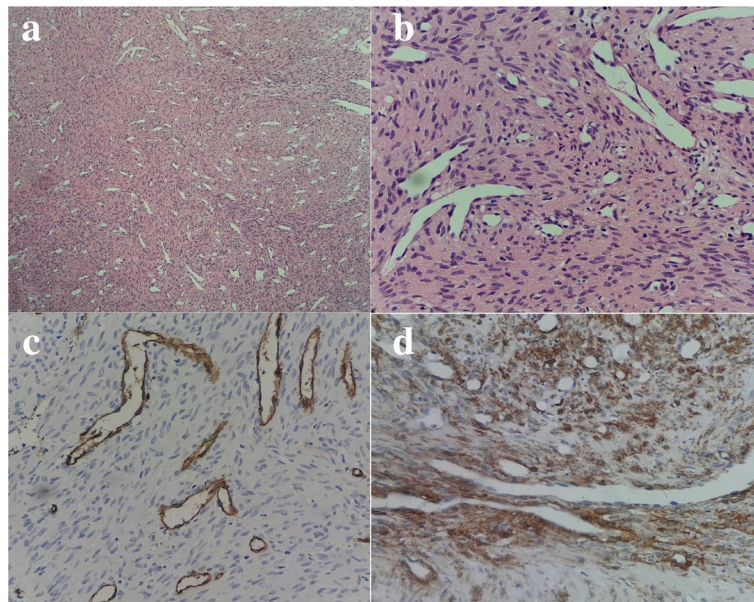


Fig. 3 Pathologic findings. Histopathologically (**a** and **b**), the tumor is composed of several slit-like vascular channels with occasional stag-horn appearing structures, surrounded by numerous spindle cells (H&E stain, low and high magnification, respectively). Immunohistochemistry shows positive staining for CD31 and CD34 in endothelial cells of blood vessels (**c**) and also positive staining for smooth muscle actin (SMA) in spindle cells (**d**)

HPC is primarily a tumor of adults, with the median age of 45 years upon presentation, and without predilection to either sex [5]. The clinical and radiological features of HPC are not specific nor characteristic and diagnosis is made by histopathological examination [8]. Patients usually present with a painless mass that grows slowly [8]. The typical appearance of HPC on the CT scan is that of a well-circumscribed mass lesion with occasional calcifications. MRI may better show the heterogeneity of tumor components with areas of low and high signal intensity on T2-weighted images representing

calcifications and thrombosis/old hematoma within the mass, respectively [9].

The microscopic appearance of HPC is remarkable for branching or “staghorn” thin-walled blood vessels with densely packed spindle cells oriented randomly [10]. Solitary fibrous tumor (SFT) is a closely related entity that shows substantial overlap of clinical and morphologic characteristics with HPC, and many authors recently considered HPC and SFT as variants belonging to the same spectrum [11]. The most prominent differences in histopathological features include variable cellularity, foci of dense collagenization and strong CD34 reactivity in SFT compared with trivial variability in cellularity, minimal collagenization and focal CD34 staining in HPC [12–14]. However, HPC and SFT are indistinguishable in many instances and most of the entities under the ill-defined term of HPC have progressively escaped from this category, leaving some cases that are now recognized as cellular or malignant forms of SFT rather than HPC [15]. Most periorbital tumors identified as HPC are nowadays recognized as SFT and both may essentially be the same tumor, despite some morphologic and immunologic variations [16]. The most recent World Health Organization (WHO) classification of soft tissue tumors has rendered the term HPC obsolete and categorizes all such tumors within the SFT group [17, 18], except for those presenting in the CNS that continue to be regarded as different entities [19].

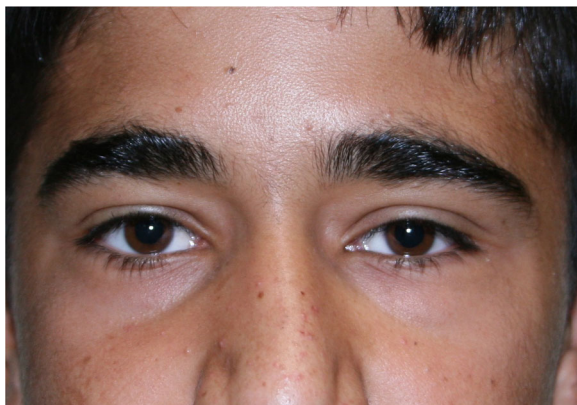

Fig. 4 Postoperative facial photograph. Frontal view of the patient 5 years after the surgery, showing complete resolution of inferolateral orbital fullness

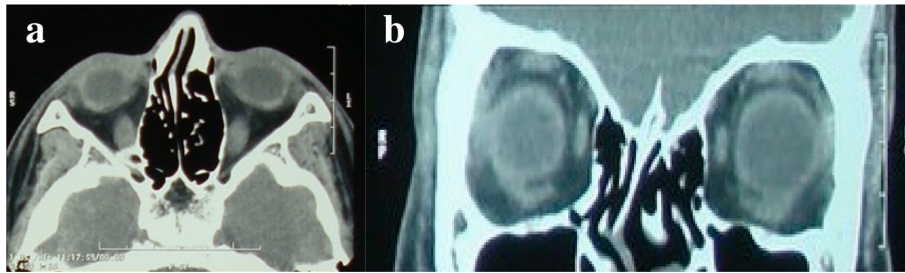


Fig. 5 Postoperative imaging. Orbital CT scan reveals mild secondary hyperostosis in the previous location of the mass, with reasonable healing and no remnant of the original tumor (**a**: axial section, **b**: coronal section)

Immunohistochemically, HPCs show reactivity for CD34, vimentin, and SMA, but are mostly negative for desmin and S-100 protein [10, 11, 15]. Despite the potentially malignant/aggressive nature of HPCs, attempts at prediction of clinical behavior of the tumor based on pathological characteristics have largely failed, which makes HPC an unpredictable neoplasm [8, 20]. Nevertheless, features like tumor size (diameter greater than 6.5 cm), mitotic activity (more than 4 mitoses per 10 high power fields), hypercellularity, anaplasia, necrosis and hemorrhage have been reported as indicators of malignant behavior [5, 8].

The treatment of choice for HPC is complete en-bloc surgical excision whenever possible, because these tumors are most often circumscribed or enclosed by a pseudocapsule [7, 11]. Completeness of surgical resection positively affects survival, while incomplete excision (piece-meal resection) or incisional biopsy are associated with local spread, recurrence and metastasis [7, 11]. However, as in our case, complete tumor resection can occasionally be challenging due to its friable and highly-vascular nature [21]. Local recurrence rate is 33% [20] and it typically occurs years later in those who had piece-meal tumor resection [5, 8]. Therefore, long term follow up is essential to detect possible recurrence or metastasis. Therapeutic options available for recurrent HPC include further attempts at surgical excision, orbital exenteration, excision combined with adjuvant radiotherapy, and chemotherapy [6, 21].

Recent advances have been made in the understanding of the genetic basis of SFT/HPC [22]. SFTs are consistently associated with NAB2-STAT6 gene fusions [23, 24]. NAB2 (NGFI-A binding protein 2) is a transcriptional repressor of early growth response genes (EGR1). STAT6 (signal transducer and activator of transcription 6) is a transcriptional activator that has a role in interleukin 4 signaling [25]. NAB2 and STAT6 are both located closely on the chromosomal band 12q13. Their fusion results in the production of a chimeric protein that induces cellular proliferation through the activation of EGR1 [23, 24]. It has been shown that nuclear expression of the carboxy

terminal part of STAT6 was highly specific and sensitive for SFT, allowing SFT to be distinguished from its histological mimics [26].

In conclusion, an extremely unusual site of involvement (zygomatic bone) by a rare tumor (HPC/SFT) is reported and the relevant literature is reviewed. Complete surgical excision provides the most effective treatment, although postoperative follow up is required for a long period of time.

Abbreviations

EGR1: Early growth response; HPC: Hemangiopericytoma; IHC: Immunohistochemistry; NAB2: NGFI-A binding protein 2; SFT: Solitary fibrous tumor; SMA: Smooth muscle actin; STAT6: Signal transducer and activator of transcription 6

Funding

No grants or funds were received for this study.

Authors' contributions

BE and HG conceived the idea for the case study and followed the patient. ZN performed the histological examination of the tumor. HG wrote the article and BE and ZN revised it critically for important intellectual content. All authors read and approved the final manuscript.

Ethics approval and consent to participate

The study was approved by the ethics committee of Farabi Eye Hospital, Tehran University of Medical Sciences, Iran.

Consent for publication

Written informed consents were obtained from the parents for publication of this Case Report and accompanying images. A copy of the written consent is available for review by the editors of this journal.

Competing interests

The authors declare that they have no competing interests.

Received: 12 March 2018 Accepted: 27 April 2018

Published online: 13 May 2018

References

- Unni KK, Ivins JC, Beabout JW, Dahlin DC. Hemangioma, hemangiopericytoma, and hemangioendothelioma (angiosarcoma) of bone. *Cancer*. 1971;27(6):1403–14.
- Tang JS, Gold RH, Mirra JM, Eckardt J. Hemangiopericytoma of bone. *Cancer*. 1988;62(4):848–59.
- Dahlin DC. Bone tumors: general aspects and data on 8,452 cases. 4th ed. Springfield: Charles C Thomas; 1986. p. 394–405.
- Asrani S, Dhirawani RB, Jain S, Arora I. Hemangiopericytoma – rarest of the rare at uncommon site. *J Oral Med Oral Surg Oral Pathol Oral Radiol*. 2017; 3(3):179–82.

5. Enzinger FM, Smith BH. Hemangiopericytoma. An analysis of 106 cases. *Hum Pathol*. 1976;7(1):61–82.
6. Bernardini FP, de Conciliis C, Schneider S, Kersten RC, Kulwin DR. Solitary fibrous tumor of the orbit: is it rare? Report of a case series and review of the literature. *Ophthalmology*. 2003;110(7):1442–8.
7. Henderson JW, Farrow GM. Primary orbital hemangiopericytoma. An aggressive and potentially malignant neoplasm. *Arch Ophthalmol*. 1978;96(4):666–73.
8. Pandey M, Kothari KC, Patel DD. Haemangiopericytoma: current status, diagnosis and management. *Eur J Surg Oncol*. 1997;23:282–5.
9. Kikuchi K, Kowada M, Sageshima M. Orbital hemangiopericytoma: CT, MR, and angiographic findings. *Comput Med Imaging Graph*. 1994;18(3):217–22.
10. Furusato E, Valenzuela IA, Fanburg-Smith JC, Auerbach A, Furusato B, Cameron JD, et al. Orbital solitary fibrous tumor: encompassing terminology for hemangiopericytoma, giant cell angiofibroma, and fibrous histiocytoma of the orbit: reappraisal of 41 cases. *Hum Pathol*. 2011;42(1):120–8.
11. Park MS, Araujo DM. New insights into the hemangiopericytoma/solitary fibrous tumor spectrum of tumors. *Curr Opin Oncol*. 2009;21(4):327–31.
12. Goldsmith JD, van de Rijn M, Syed N. Orbital hemangiopericytoma and solitary fibrous tumor: a morphologic continuum. *Int J Surg Pathol*. 2001;9(4):295–302.
13. Ribeiro SF, Chahud F, Cruz AA. Orbital hemangiopericytoma/solitary fibrous tumor in childhood. *Ophthal Plast Reconstr Surg*. 2012;28(3):e58–60.
14. Rose AM, Kabiru J, Rose GE. A rare case of orbital haemangiopericytoma arising in childhood. *Orbit*. 2013;32(6):384–6.
15. Gengler C, Guillou L. Solitary fibrous tumour and haemangiopericytoma: evolution of a concept. *Histopathology*. 2006;48(1):63–74.
16. Vilardell F, Huerva V, Abó A, Sánchez MC, Matias-Guiu X. Orbital solitary fibrous tumor: Report of a three cases series. *Int J Ophthalmic Pathol*. 2014;3:3.
17. Fletcher CDM. World Health Organization, International Agency for Research on Cancer. WHO Classification of Tumours of Soft Tissue and Bone. 4th ed. Lyon: IARC Press; 2013.
18. DeVito N, Henderson E, Han G, Reed D, Bui MM, Lavey R, et al. Clinical Characteristics and Outcomes for Solitary Fibrous Tumor (SFT): A Single Center Experience. *PLoS One*. 2015;10(10):e0140362.
19. Yalcin CE, Tihan T. Solitary Fibrous Tumor/Hemangiopericytoma Dichotomy Revisited: A Restless Family of Neoplasms in the CNS. *Adv Anat Pathol*. 2016;23(2):104–11.
20. Croxatto JO, Font RL. Hemangiopericytoma of the orbit: a clinicopathologic study of 30 cases. *Hum Pathol*. 1982;13(3):210–8.
21. Shinder R, Jackson TL, Araujo D, Prieto VG, Guadagnolo BA, Esmaeli B. Preoperative radiation therapy in the management of recurrent orbital hemangiopericytoma. *Ophthal Plast Reconstr Surg*. 2011;27(5):e126–8.
22. Thway K, Ng W, Noujaim J, Jones RL, Fisher C. The Current Status of Solitary Fibrous Tumor: Diagnostic Features, Variants, and Genetics. *Int J Surg Pathol*. 2016;24(4):281–92.
23. Robinson DR, Wu YM, Kalyana-Sundaram S, Cao X, Lonigro RJ, Sung YS, et al. Identification of recurrent NAB2-STAT6 gene fusions in solitary fibrous tumor by integrative sequencing. *Nat Genet*. 2013;45(2):180–5.
24. Chmielecki J, Crago AM, Rosenberg M, O'Connor R, Walker SR, Ambrogio L, et al. Whole exome sequencing identifies a recurrent NAB2-STAT6 fusion in solitary fibrous tumors. *Nat Genet*. 2013;45(2):131–2.
25. Petrovic A, Obéric A, Moulin A, Hamedani M. Ocular adnexal (orbital) solitary fibrous tumor: nuclear STAT6 expression and literature review. *Graefes Arch Clin Exp Ophthalmol*. 2015;253(9):1609–17.
26. Doyle LA, Vivero M, Fletcher CD, Mertens F, Hornick JL. Nuclear expression of STAT6 distinguishes solitary fibrous tumor from histologic mimics. *Mod Pathol*. 2014;27(3):390–5.

Ready to submit your research? Choose BMC and benefit from:

- fast, convenient online submission
- thorough peer review by experienced researchers in your field
- rapid publication on acceptance
- support for research data, including large and complex data types
- gold Open Access which fosters wider collaboration and increased citations
- maximum visibility for your research: over 100M website views per year

At BMC, research is always in progress.

Learn more biomedcentral.com/submissions

