

RESEARCH

Open Access



Three-year follow-up of posterior chamber phakic intraocular lens with a central port design after deep anterior lamellar keratoplasty

Belén Alfonso-Bartolozzi¹, Carlos Lisa¹, Luis Fernández-Vega-Cueto^{1*} , Begoña Baamonde¹, David Madrid-Costa² and José F. Alfonso¹

Abstract

Background: To evaluate clinical outcomes of the Visian implantable collamer lens (ICL) with a central port to correct myopia and astigmatism after deep anterior lamellar keratoplasty (DALK) for keratoconus throughout 3 years of follow-up.

Methods: This study included 20 eyes of 20 patients that underwent V4c ICL (13 eyes with a spherical ICL and 7 eyes with a toric ICL) implantation after DALK. Uncorrected (UDVA) and corrected (CDVA) distance visual acuities, refraction, intraocular pressure (IOP), endothelial cell density (ECD), and vault were analyzed.

Results: The mean UDVA improved from the preoperative 1.18 ± 0.33 logMAR to 0.25 ± 0.14 logMAR at 6 months after surgery ($P < 0.0001$) and remained unchanged throughout the whole follow-up ($P = 0.4$). All eyes gained lines of CDVA compared to preoperative values. At the last follow-up visit, all eyes achieved CDVA of 0.2 logMAR or better and 13 eyes (65%) 0.1 logMAR or better. At 6 months post-surgery, all eyes (100%) had a spherical equivalent within ± 1.50 D, and 19 (95%) within ± 1.00 D. The mean manifest spherical equivalent was stable over the postoperative follow-up ($P = 0.25$). No significant increase in IOP occurred in any case throughout the 3 years of follow-up. The loss in ECD from the preoperative baseline at the last follow-up visit was 2.27%.

Conclusions: The clinical outcomes suggest that the V4c ICL implantation for correction of myopia and regular astigmatism in post-DALK eyes was satisfactory in terms of effectiveness, safety, and stability during 3 years of follow-up.

Keywords: Deep anterior lamellar keratoplasty, DALK, Implantable collamer lens, ICL

Background

Deep anterior lamellar keratoplasty (DALK) is becoming the preferred option for corneal transplantation in patients affected by a corneal disease in which the endothelium is healthy and can be preserved [1]. However, residual postoperative refractive error may represent a significant limiting factor for visual rehabilitation.

The mean spherical equivalent reported after DALK ranges from -6.54 to -1.50 D and the mean refractive astigmatism from 2.25 to 4.55 D [2–7]. Hence, the patient's visual rehabilitation might be limited, even in uncomplicated DALK, due to high residual refractive error and/or anisometropia. Conservative options such as contact lenses or spectacles can be considered for the management of postoperative ametropia. However, anisometropia or high degrees of refractive error corrected with spectacles may not be well tolerated. Furthermore, some patients may experience contact lens intolerance, difficulties with lens handling or lack of motivation for

*Correspondence: lfvc@fernandez-vega.com

¹ Fernández-Vega Ophthalmological Institute, Avda. Dres. Fernández-Vega 114. 33012, Oviedo, Spain

Full list of author information is available at the end of the article



© The Author(s) 2022. **Open Access** This article is licensed under a Creative Commons Attribution 4.0 International License, which permits use, sharing, adaptation, distribution and reproduction in any medium or format, as long as you give appropriate credit to the original author(s) and the source, provide a link to the Creative Commons licence, and indicate if changes were made. The images or other third party material in this article are included in the article's Creative Commons licence, unless indicated otherwise in a credit line to the material. If material is not included in the article's Creative Commons licence and your intended use is not permitted by statutory regulation or exceeds the permitted use, you will need to obtain permission directly from the copyright holder. To view a copy of this licence, visit <http://creativecommons.org/licenses/by/4.0/>. The Creative Commons Public Domain Dedication waiver (<http://creativecommons.org/publicdomain/zero/1.0/>) applies to the data made available in this article, unless otherwise stated in a credit line to the data.

contact lenses fitting. In these patients, several surgical refractive procedures have been studied to improve visual rehabilitation.

The Visian implantable collamer lens (ICL, Staar Surgical AG, Nidau, Switzerland) implantation has been demonstrated to be an effective, safe, and predictable surgical procedure to correct myopia, astigmatism, and hyperopia [8–10]. However, the knowledge is limited to a few studies in patients with a previous penetrating keratoplasty (PKP) or DALK [11–16]. Although these studies have shown promising visual and refractive outcomes, the ICLs evaluated were the former models and the follow-up periods were limited, not spanning more than 24 months. The potential complications associated with ICL implantation increase with time [17–20]. The V4c ICL model (V4c), developed by Shimizu et al. [21], incorporates a central port design that allows the flow of the aqueous fluid through the lens [22, 23], preserving the normal physiology of the anterior segment of the eye and preventing potential complications compared to the previous ICL models [24]. This new design with the central hole could be particularly beneficial in patients with a keratoplasty, minimizing what could represent a potential added risk for cataract development or compromise graft health. This study aims to evaluate clinical outcomes throughout a 3-year follow-up of the ICL V4c implantation in eyes with previous DALK.

Methods

This retrospective, observational study evaluated eyes with previous DALK and subsequent implantation of the myopic or toric V4c model (STAAR Surgical Inc) to correct the refractive error at the Fernández-Vega Ophthalmological Institute, Oviedo, Spain. This study followed tenets of the Declaration of Helsinki and full ethical approval from the institute was obtained. After receiving a complete description of the possible consequences of surgery, all patients provided informed consent.

The indication for DALK was advanced keratoconus in all cases. All DALK surgeries were performed by the same surgeon (JFA) using Anwar' technique [25]. The time between the DALK procedure and ICL implantation to correct the residual refractive was at least 6 months after complete suture removal. Before the ICL implantation, all the patients were phakic, had a clear corneal graft, refractive stability for at least 6 months after all sutures were removed, endothelial cell density (ECD) greater than 1500 cells/mm², and a minimum corneal thickness of 400 μm. None of the patients had ocular or systemic diseases with a potential impact on graft survival. Furthermore, patients had met the general criteria for ICL implantation: refractive error in the range correctable with the V4c ICL, anterior chamber depth

(ACD) greater than 3.0 mm measured from the corneal endothelium to the anterior lens capsule.

Eyes with a topographic cylinder of more than 3.00 D and regular topographic astigmatism were implanted with a toric ICL. In eyes with a topographic cylinder less than 3.00 D, a spherical ICL was implanted. In these cases, to reduce the topographic cylinder, clear corneal incisions (CCI) were performed on the steep axis. In eyes with a topographic cylinder between 0.75 and 1.25 D, one CCI (3.0–3.2 mm, respectively); in eyes with astigmatism between 1.50 and 2.50 D, two opposite CCI (3.0 mm for 1.50 D and 3.2 mm for astigmatism between 1.75 and 2.50 D) were carried out in the steep axis. All incisions were performed with a bevel-up steel blade (Equipisa S.A., Madrid, Spain). ICL power calculation was performed using a modified vertex formula provided by the manufacturer (Staar Surgical) with a target of emmetropia as postoperative refraction. The size of the ICL was individually calculated for each eye based on the measurements of horizontal white-to-white (WTW) distance, ACD and angle-to-angle distance obtained with anterior segment optical coherence tomography (AS-OCT, Visante, Carl Zeiss Meditec AG).

All surgeries were carried out by the same surgeon (JFA) according to the standard procedure previously described [26, 27]. Postoperative follow-up was 3 years in all cases. The study evaluated the outcomes at preoperative, 6, 12, and 36 months postoperative visits. The examinations included measurement of uncorrected (UDVA) and corrected (CDVA) distance visual acuities, manifest refraction, slit-lamp examination, intraocular pressure (IOP) measured by Goldmann applanation tonometry, ECD (SP 3000P, Topcon Europe) and fundoscopy. The central distance between the ICL and the crystalline lens (vault) was assessed using AS-OCT. The vault between the crystalline lens and the ICL was measured perpendicular to the lens apex or at the narrowest point.

Data analysis was performed using SPSS for Windows, version 14.0 (SPSS Inc., Chicago, IL). Normality was first checked with the Kolmogorov-Smirnov test and a repeated-measures analysis of variance (ANOVA) with a Bonferroni post hoc test was performed thereafter. Differences were considered statistically significant when the *P* value was less than 0.05.

Results

This study included 20 eyes of 20 patients (15 men and 5 women). The mean time between the DALK procedure and ICL implantation to correct the refractive error was 26.2 ± 12.27 months (range 14–55 months). All patients completed the follow-up period of 3 years and attended all the follow-up visits. Table 1 summarizes preoperative demographic data of the patients and ICL characteristics.

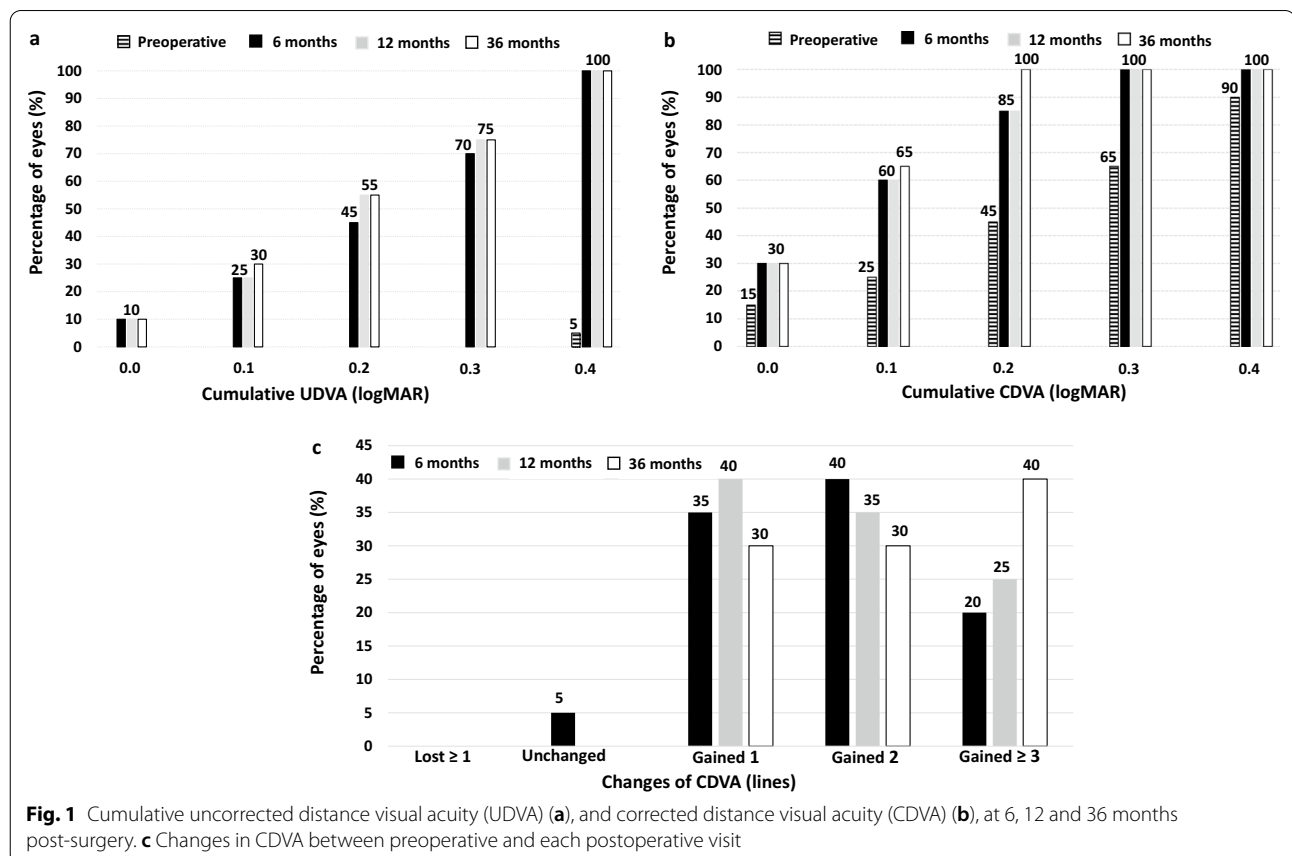
Table 1 Preoperative patient demographics and ICL characteristics

	Mean ± SD	Range (min, max)
Age (years)	39.85 ± 10.40	(25, 62)
Refraction sphere (D)	- 5.78 ± 3.87	(- 15.00, - 0.50)
Refraction cylinder (D)	- 2.36 ± 1.40	(- 5.00, - 0.50)
Spherical equivalent (D)	- 6.96 ± 3.89	(- 16.13, - 2.25)
Minimum keratometry (D)	43.95 ± 2.00	(40.75, 48.00)
Maximum keratometry (D)	46.78 ± 2.19	(42.25, 51.00)
Keratometric cylinder (D)	2.83 ± 1.57	(1.00, 6.00)
Corneal thickness (µm)	507 ± 64	(407, 581)
ACD (mm)	3.49 ± 0.25	(3.00, 3.93)
WTW (mm)	12.26 ± 0.48	(11.45, 13.27)
ATA (mm)	11.94 ± 0.42	(11.00, 13.20)
ECD (cells/mm ²)	2173 ± 533	(1527, 3347)
IOP (mmHg)	12.65 ± 1.66	(10, 16)
ICL sphere power (D)	- 7.93 ± 3.98	(- 16.50, - 3.50)
ICL toric power (D)*	4.36 ± 0.99	(3.50, 6.00)

ICL = implantable collamer lens; D = diopters; ACD = anterior chamber depth; WTW = white-to-white; ATA = angle-to-angle; ECD = endothelial cell density; IOP = intraocular pressure; SD = standard deviation. *For 7 eyes that were implanted with a toric ICL

Thirteen eyes (65%) were implanted with a spherical ICL and 7 eyes (35%) with a toric ICL. The distribution of the lens sizes implanted were 13.7 mm in 1 eye (5%), 13.2 mm in 10 eyes (50%), 12.6 mm in 5 eyes (25%) and 12.1 mm in 4 eyes (20%).

The UDVA improved from 1.18 ± 0.33 logMAR preoperatively to 0.25 ± 0.14 logMAR at 6 months after surgery ($P < 0.0001$) and subsequently remained stable throughout the whole follow-up period (0.25 ± 0.13 logMAR and 0.24 ± 0.13 logMAR, at 12 and 36 months, respectively, $P = 0.4$). The efficacy index (mean post-operative UDVA/mean preoperative CDVA) was 1.06, 1.05, and 1.08 at 6, 12, and 36 months after surgery, respectively. At the last follow-up visit, the UDVA was 0.3 logMAR (20/40) in 15 eyes (75%) (Fig. 1a). The mean CDVA increased from the preoperative 0.28 ± 0.15 logMAR to 0.14 ± 0.09 logMAR at 6 months after surgery ($P = 0.003$) and remained unchanged over the whole follow-up period (0.13 ± 0.10 logMAR and 0.11 ± 0.08 logMAR, at 12 and 36 months, respectively, $P = 0.09$). At the last visit, all eyes achieved CDVA of 0.2 logMAR or better ($\geq 20/32$) and 13 eyes (65%) had a value of 0.1 logMAR or better ($\geq 20/25$) (Fig. 1b). Furthermore, all eyes gained lines of CDVA compared to preoperative



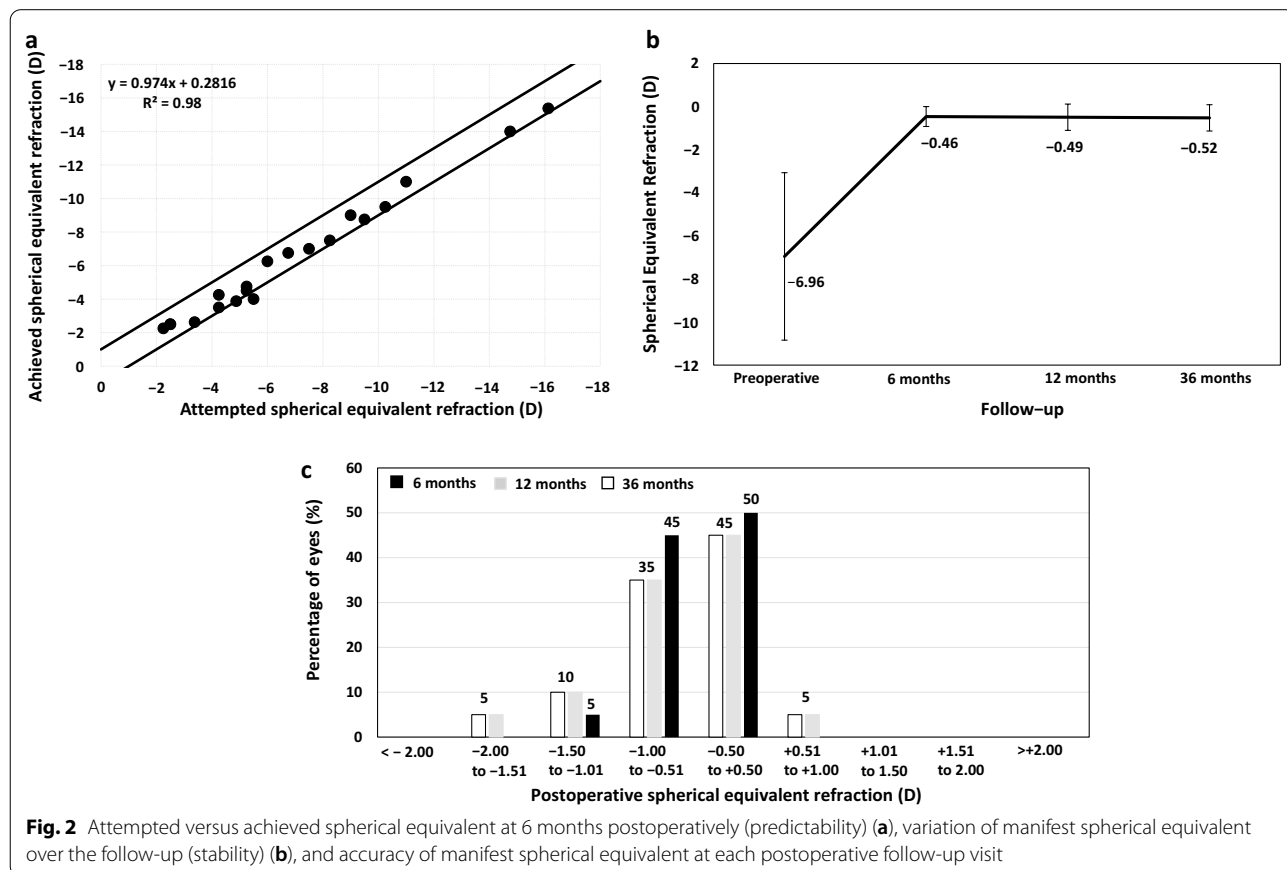
values (Fig. 1c). The safety index (ratio between the postoperative CDVA at the last visit and the preoperative CDVA) was 1.40.

Figure 2a displays the correlation analysis between attempted versus achieved spherical equivalent refraction at 6 months post-surgery. All eyes (100%) had a spherical equivalent within ± 1.50 D and 19 (95%) within ± 1.00 D. The mean manifest spherical equivalent remains stable over the postoperative follow-up ($P=0.25$) (Fig. 2b). At 12 and 36 months, 17 eyes (85%), had a spherical equivalent within ± 1.00 D (Fig. 2c). In the 7 eyes implanted with toric ICL, the refractive cylinder 6 months after surgery was ≤ 0.50 D. In 6 out of 7 eyes, the refractive cylinder was unchanged over follow-up. In one eye (14.8%), the ICL was rotated between the 6- and 12-month follow-up visits. This ICL rotation induced mixed astigmatism ($+1.50 - 2.00 \times 20^\circ$), leading to a decrease of 2 lines of UDVA, but CDVA remained unchanged. The vault in the 12-month visit was $700 \mu\text{m}$. As the CDVA was maintained, and the induced mixed was well-tolerated with spectacles, no re-centering maneuverer or ICL exchange for a larger size was performed. The visual and refractive outcomes remained unchanged between the 12- and 36-month follow-up visits.

The IOP was stable over the whole follow-up (12.6 ± 1.66 mmHg preoperatively and 12.9 ± 1.66 mmHg, 12.8 ± 2.31 mmHg, and 12.9 ± 2.36 mmHg at 6, 12, and 36 months, respectively, $P=0.25$) (Fig. 3a). At the end of the follow-up, the largest proportion of the eyes experienced a reduction or maintenance of the IOP compared with the preoperative value (12 eyes, 60%), 4 eyes (20%) showed an increased 1–2 mmHg, and 2 eyes (20%) had an increased 3–4 mmHg (Fig. 3b). No significant increase in IOP (> 20 mmHg or an increase higher than 5 mmHg) occurred in any case throughout the 36 months of follow-up.

Regarding the ECD, there were no significant changes at any time of follow-up ($P=0.1$) (Fig. 4). The loss in ECD from the preoperative compared with the last follow-up visit was 2.27%.

The mean postoperative vault between the crystalline lens and ICL under mesopic lighting conditions was slightly reduced among visits ($373 \pm 217 \mu\text{m}$, $361 \pm 207 \mu\text{m}$, and $345 \pm 193 \mu\text{m}$ at 6, 12, and 36 months postoperatively, respectively). Multiple comparisons showed statistically significant differences among all postoperative visits ($P=0.03$). The analysis of the postoperative distribution of the vault (Fig. 5) showed that



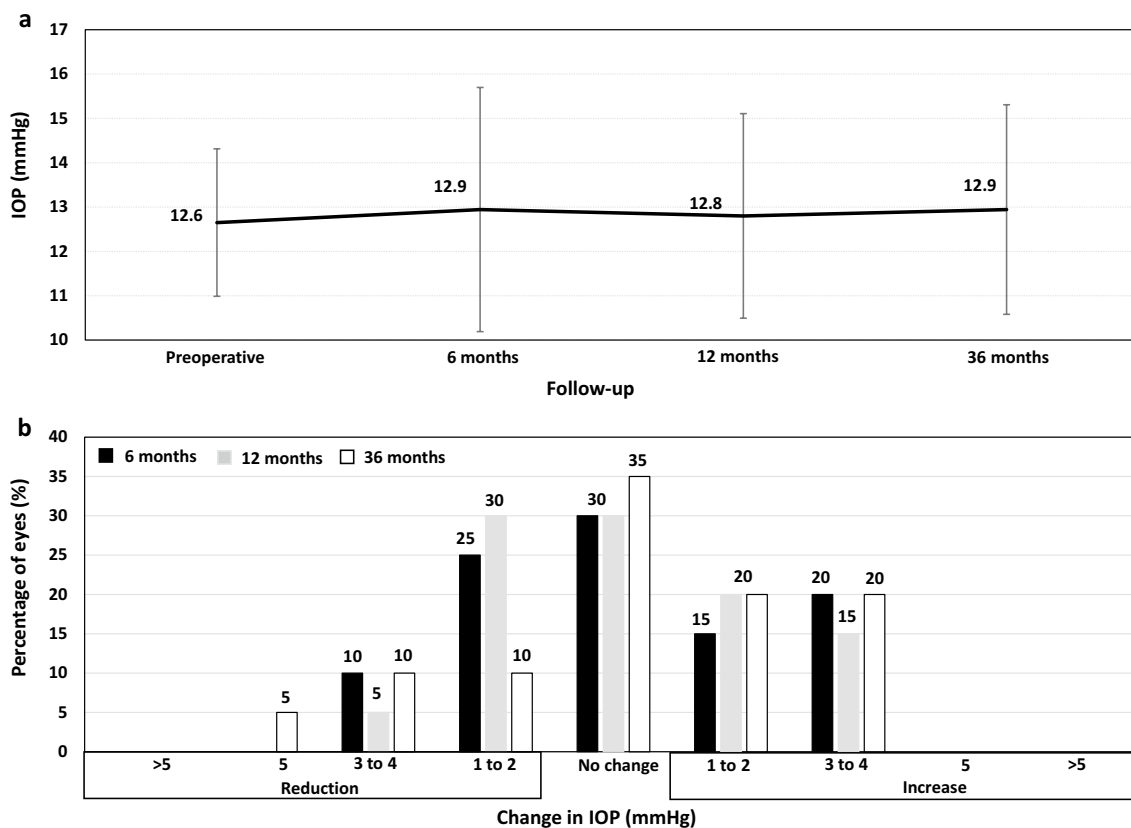


Fig. 3 Changes in the mean intraocular pressure (IOP) over the whole follow-up (a), and variation in IOP between preoperative and each postoperative follow-up visit (b)

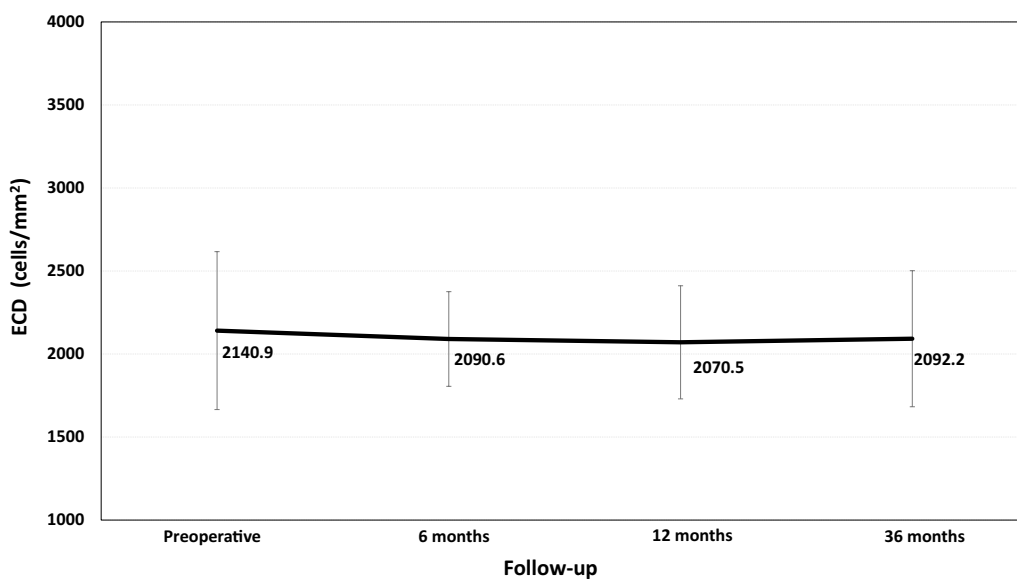


Fig. 4 Mean endothelial cell density (ECD) (cells/mm²) throughout the follow-up

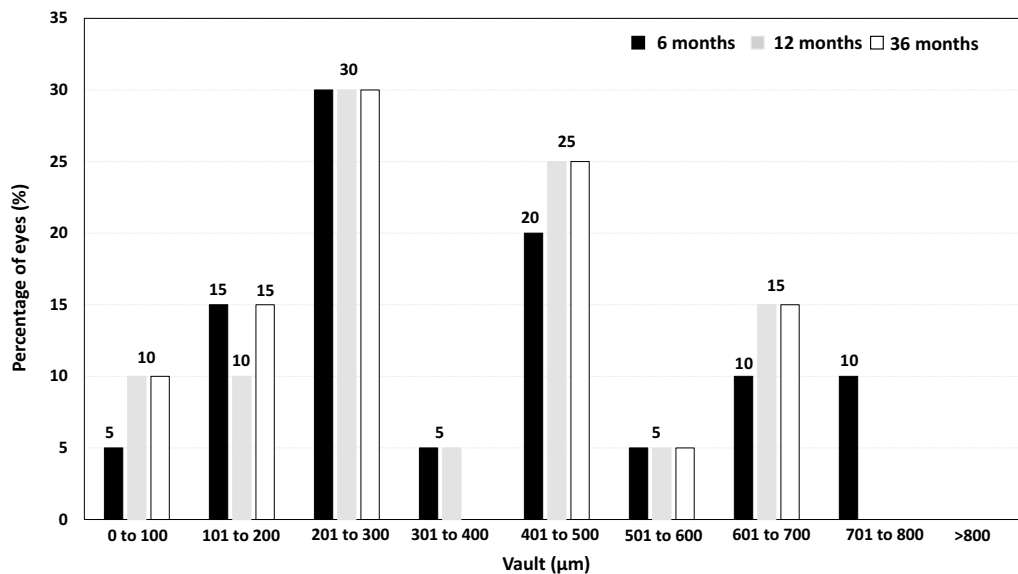


Fig. 5 Distribution of eyes according to the vault, measured in microns, at 6, 12, and 36 months postoperatively

no eyes had a vault higher than 800 µm at any visit, and approximately 20% of eyes had a vault lower than 200 µm throughout the follow-up.

There were no intraoperative complications, and no eyes required ICL explantation or exchange. Throughout the follow-up, no cases of anterior subcapsular opacity, cataract, pigment dispersion glaucoma, pupillary block, or other vision-threatening complications were reported. As previously detailed, one eye implanted with toric ICL had an ICL rotation.

Discussion

In the cohort analyzed, the post-DALK (before ICL implantation) mean spherical equivalent was -6.96 ± 3.89 D and the mean refractive cylinder -2.36 ± 1.40 D. These results agree with those previously reported [2–7] and indicate that whether the refractive error is not well tolerated with spectacles or contact lenses or induces anisometropia may lead to unsatisfactory visual rehabilitation. To overcome this, a variety of refractive surgical procedures have been evaluated. Corneal refractive procedures have shown encouraging results [28–31], however, these options were not appropriate in this group of eyes because of high myopia and astigmatism, dry eye and/or low corneal thickness for the attempted refractive error.

The results of this study of 20 eyes that underwent V4c ICL implantation to correct myopia or astigmatism after DALK were satisfactory. The efficacy index of the procedure was higher than 1.0 at all follow-up visits, which implies that the postoperative UDVA was equal to or

better than preoperative CDVA. Furthermore, at the last follow-up visit, all eyes had gained lines of CDVA compared to preoperative values (Fig. 1c). The UDVA was 0.3 logMAR (20/40) in 15 eyes (75%) at the last follow-up visit and all eyes achieved CDVA of 0.2 logMAR or better ($\geq 20/32$). The safety index was 1.40. It is important to note that after DALK, the cornea may present optical irregularities such as irregular astigmatism or increased higher-order aberrations, which might represent a potential factor in limiting the visual restoration after ICL implantation. In those cases, a combined procedure, such as intrastromal corneal ring segments implantation for corneal regularization and subsequently ICL for the residual refractive error correction, might be a better approach. Our group found this approach very effective in keratoconus patients [32], however, it should be analyzed in post-DALK eyes to evaluate the effectiveness and safety in these cases.

The visual outcomes were stable throughout the follow-up, confirming the efficacy, safety, and stability of the procedure. On the contrary to what we found in this study in post-DALK eyes, the efficacy index of the V4c ICL implantation in virgin corneas may worsen over time owing to an axial length elongation and consequently increase in myopia and decrease in UDVA [27]. It is noteworthy that this procedure is carried out at an older age in post-DALK patients, and thus, the risk of axial length elongation is lower. However, in younger patients, this aspect should be assessed preoperatively. Although LASIK and PRK have shown efficacy and safety in post-DALK [28–31], and a laser touch-up can be effectively

and safely planned, this risk should be evaluated and explained to the patients.

Regarding refractive outcomes, at 6 months, the mean spherical equivalent was -0.46 ± 0.46 D, with 95% of the eyes with a spherical equivalent within ± 1.00 D. In the 7 eyes implanted with toric ICL, the refractive cylinder 6 months after surgery was ≤ 0.50 D. Therefore, these results show that spherical and toric V4c ICL are capable of correcting for myopia and astigmatism effectively in post-DALK eyes. Furthermore, the refractive outcomes remained stable over the 3 years of follow-up in all cases except in one eye implanted with toric ICL. In this eye, the refraction changed from plano at 6 months to $+1.50 - 2.00 \times 20^\circ$ at 12 months, and the UDVA dropped 2 lines, while CDVA remained unchanged. After slit-lamp examination, a rotation of 15 degrees from the original position was observed. As the CDVA was maintained, and the induced mixed astigmatism was well-tolerated with spectacles, we opted for a conservative strategy protecting the graft from another surgical procedure and no re-centering maneuver or ICL exchange for a larger size was performed. It should be noted that our criterion for toric ICL implantation was regular astigmatism confirmed by topography. The combination of toric ICL rotated off-axis with an irregular cornea could cause a decrease not only in UDVA but also in CDVA thereby requiring another surgical intervention for ICL re-centering or ICL exchange. It should be kept in mind that unlike patients with a virgin cornea whose aim must be to achieve emmetropia, the main objective for post-DALK patients on the other hand, should be to reduce the refractive error as much as possible to avoid anisometropia and improve the spectacle tolerance. Considering this, our study showed that the implantation of spherical ICLs combined with CCI is also an excellent alternative to reduce myopia and astigmatism, avoiding the possible complications derived from the toric rotation of the ICL.

No direct comparison with previous studies of this model of ICL in post-DALK eyes is possible because, to the best of our knowledge, this is the first study to evaluate V4c ICL in eyes with a previous DALK. Four previous studies have evaluated the correction of residual refractive error with a former model of ICL in post-PKP eyes and only two studies in post-DALK eyes. Akcay et al. [11] reported that one eye underwent toric ICL implantation to treat high myopia and astigmatism after PKP. Alfonso et al. [12] evaluated 15 eyes that had spherical or toric ICL (9 eyes with a spherical ICL and 6 eyes with a toric ICL) after PKP with a follow-up of 2 years. Mehta et al. [13] studied three post-PKP with a follow-up ranging between 3 and 14 months. Iovieno et al. [14], in turn, reported the outcomes of toric ICL implantation in 7 post-keratoplasty eyes (6 PKP

and 1 DALK) over a follow-up range between 4 and 22 months. Qin et al. [15] investigated the implantation of toric ICL in 9 DALK cases over 2 years of follow-up. In the Alfonso et al.'s study [16], the ICL was implanted as Piggyback IOL for the correction of residual refractive error in 7 post-DALK pseudophakic eyes, with a mean follow-up of 13.32 ± 13.57 months. All these studies concluded that the ICL implantation significantly reduced the refraction with a high accuracy rate (with most eyes within ± 1.00 D of the desired refraction), and a significant improvement in UDVA and CDVA and most of the eyes maintaining or improving the preoperative CDVA. Not surprisingly, our visual and refractive outcomes with the V4c ICL are in line with those previously published with the prior ICL model, but our study also confirms that these results remained stable over a longer follow-up period than those previously reported. Hence, these values confirm the excellent visual and refractive results of this procedure in post-keratoplasty eyes.

However, we should be cautious and consider that any intraocular procedure may have associated potential adverse events. The rate of adverse events with the previous ICL models (such as cataracts, ECD loss, pigment dispersion syndrome) increased with time [17–20, 33] and the most extended follow-up in post-keratoplasty eyes reported up to now not spanning more than 2 years. The incidence of complications has significantly decreased with the V4c model in comparison to those reported with the previous ICL models (non-hole ICL). The central hole of the V4c ICL offers surgical advantages over previous ICL models (non-hole ICL) models, reducing ocular trauma and simplifying the surgery since no preoperative iridotomy or intraoperative iridectomy is necessary to prevent IOP increase [33, 34]. Furthermore, the hole-equipped ICL allows for maintaining the normal physiology of the anterior segment of the eye since aqueous humor may flow through the hole of the lens, preventing potential complications [24].

Fernandes et al. [33] reported that the prevalence of cataracts with the previous models of ICL was 5.2%, while this percentage dropped to almost 0% (0.17%) with V4c ICL [22]. The main risk factor for ICL-induced cataracts with non-hole ICL was a vault lower than $200 \mu\text{m}$ [33]. In our study in post-DALK eyes, we did not find cataracts, although approximately 20% of the cases had a vault lower than $200 \mu\text{m}$. Recently, our research group reported the most extended follow-up with V4c ICL published up to now in patients with the virgin cornea (84 eyes followed for 7 years) [27], in which approximately 20% of the eyes had a vault lower than $200 \mu\text{m}$, and we did not find cataract formation in any cases throughout the follow-up. Hence, it is plausible to suggest that

the central hole of the V4c ICL model prevents cataract development, even in eyes with a low vault, confirming the safety of this model [35].

Regarding IOP and ECD, our results did not yield a statistically significant change over the follow-up. The IOP was stable over the 36 months of follow-up. At the end of the follow-up, most eyes showed a reduction or maintenance in IOP from the preoperative value, with no eyes experiencing a significant increase in IOP (>20 mmHg or an increase higher than 5 mmHg) throughout the whole follow-up. In turn, the loss in ECD from the preoperative at the last follow-up visit was 2.27%. This finding agrees with those previously reported, suggesting that the V4c ICL does not promote significant ECD loss over time [24]. In addition to the benefits of the central hole design to prevent an IOP increase and ECD loss, it should note that no eyes showed a vault higher than 800 µm at any follow-up visit, which might represent a potential risk factor [36].

All these findings suggest that the central hole design of the V4c ICL might provide safety to the outstanding visual and refractive outcomes previously reported with the previous model, and it is essential in post-keratoplasty eyes. However, despite these encouraging results, it is important to note the limitations of our study; its retrospective design and the lack of a control group. Therefore, further long-term studies with a randomized comparative prospective design are necessary to evaluate the possible complications of this technique in post-DALK eyes.

Conclusion

Our clinical outcomes suggest that the V4c ICL implantation for correction of myopia and regular astigmatism in post-DALK eyes was satisfactory in terms of effectiveness, safety, and stability during 3 years of follow-up, which finally indicates its viability as a surgical option for the residual refractive error correction after DALK.

Abbreviations

DALK: Deep anterior lamellar keratoplasty; PKP: Penetrating keratoplasty; ICL: Implantable collamer lens; ECD: Endothelial cell density; ACD: Anterior chamber depth; CCI: Clear corneal incisions; WTW: White-to-white; AS-OCT: Anterior segment optical coherence tomography; UDVA: Uncorrected distance visual acuity; CDVA: Corrected distance visual acuity; IOP: Intraocular pressure.

Acknowledgements

Not applicable.

Author contributions

BAB: Conception and design of the study; Analysis and interpretation of data; writing the manuscript. CL: Conception and design of the study; Analysis and interpretation of data; Critical revision of the manuscript. LFVC: Conception and design of the study; Analysis and interpretation of data; Critical revision of the manuscript. BB: Conception and design of the study; Analysis and interpretation of data; Critical revision of the manuscript. DMC: Conception and design of the study; Analysis and interpretation of

data; Critical revision of the manuscript; Supervision. JFA: Conception and design of the study; Analysis and interpretation of data; Critical revision of the manuscript; Supervision. All authors read and approved the final manuscript.

Funding

This study was supported in part by an unrestricted Grant from STAAR Surgical to the Fernández-Vega Ophthalmological Institute.

Availability of data and materials

Not applicable.

Declarations

Ethics approval and consent to participate

This study was conducted in compliance with the tenets of the Declaration of Helsinki, and full ethical approval from the Fernández-Vega Ophthalmological Institute was obtained. After receiving a complete description of the nature of the study and the possible consequences of surgery, all patients provided written informed consent.

Consent for publication

Not applicable.

Competing interests

The authors declare that they have no competing interests.

Author details

¹Fernández-Vega Ophthalmological Institute, Avda. Dres. Fernández-Vega 114. 33012, Oviedo, Spain. ²Clinical and Experimental Eye Research Group (CEER), Optometry and Vision Department, Faculty of Optics and Optometry, Universidad Complutense de Madrid, Madrid, Spain.

Received: 9 March 2022 Accepted: 17 August 2022

Published online: 07 September 2022

References

- Reinhart WJ, Musch DC, Jacobs DS, Lee WB, Kaufman SC, Shtein RM. Deep anterior lamellar keratoplasty as an alternative to penetrating keratoplasty: a report by the American academy of ophthalmology. *Ophthalmology*. 2011;118(1):209–18.
- Song Y, Zhang J, Pan Z. Systematic review and meta-analysis of clinical outcomes of penetrating keratoplasty versus deep anterior lamellar keratoplasty for keratoconus. *Exp Clin Transplant*. 2020;18(4):417–28.
- Henein C, Nanavaty MA. Systematic review comparing penetrating keratoplasty and deep anterior lamellar keratoplasty for management of keratoconus. *Cont Lens Anterior Eye*. 2017;40(1):3–14.
- Cheng YYY, Visser N, Schouten JS, Wijdh RJ, Pels E, van Cleynenbreugel H, et al. Endothelial cell loss and visual outcome of deep anterior lamellar keratoplasty versus penetrating keratoplasty: a randomized multicenter clinical trial. *Ophthalmology*. 2011;118(2):302–9.
- Ardjomand N, Hau S, McAlister JC, Bunce C, Galaretta D, Tuft SJ, et al. Quality of vision and graft thickness in deep anterior lamellar and penetrating corneal allografts. *Am J Ophthalmol*. 2007;143(2):228–35.
- Noble BA, Agrawal A, Collins C, Saldana M, Brogden PR, Zuberbuhler B. Deep anterior lamellar keratoplasty (DALK) visual outcome and complications for a heterogeneous group of corneal pathologies. *Cornea*. 2007;26(1):59–64.
- Watson SL, Ramsay A, Dart JKG, Bunce C, Craig E. Comparison of deep lamellar keratoplasty and penetrating keratoplasty in patients with keratoconus. *Ophthalmology*. 2004;111(9):1676–82.
- Sanders DR, Doney K, Poca M, ICL in Treatment of Myopia (ITM) Study Group. United States Food and Drug Administration clinical trial of the implantable collamer lens (ICL) for moderate to high myopia: three-year follow-up. *Ophthalmology*. 2004;111(9):1683–92.
- Pesando PM, Ghiringhello MP, Di Meglio G, Fanton G. Posterior chamber phakic intraocular lens (ICL) for hyperopia: ten-year follow-up. *J Cataract Refract Surg*. 2007;33(9):1579–84.

10. Sanders DR, Schneider D, Martin R, Brown D, Dulaney D, Vukich J, et al. Toric implantable collamer lens for moderate to high myopic astigmatism. *Ophthalmology*. 2007;114(1):54–61.
11. Akcay L, Kaplan AT, Kandemir B, Gunaydin NT, Dogan OK. Toric intraocular Collamer lens for high myopic astigmatism after penetrating keratoplasty. *J Cataract Refract Surg*. 2009;35(12):2161–3.
12. Alfonso JF, Lisa C, Abdelhamid A, Montés-Micó R, Poo-López A, Ferrer-Blasco T. Posterior chamber phakic intraocular lenses after penetrating keratoplasty. *J Cataract Refract Surg*. 2009;35(7):1166–73.
13. Mehta JS, Yuen LH, Mengher LS, Papatthanassiou M, Allan BD. Correcting post-keratoplasty anisometropia with the implantable collamer phakic intraocular lens. *Clin Exp Ophthalmol*. 2010;38(8):764–7.
14. Iovieno A, Guglielmetti S, Capuano V, Allan BD, Maurino V. Correction of postkeratoplasty ametropia in keratoconus patients using a toric implantable Collamer lens. *Eur J Ophthalmol*. 2013;23(3):361–7.
15. Qin Q, Yang L, He Z, Huang Z. Clinical application of T1CL implantation for ametropia following deep anterior lamellar keratoplasty for keratoconus: a CONSORT-compliant article. *Medicine (Baltimore)*. 2017;96(8):e6118.
16. Alfonso JF, Lisa C, Alfonso-Bartolozzi B, Fernández-Vega-Cueto L, Montés-Micó R. Implantable Collamer Lens[®] for management of pseudophakic ametropia in eyes with a spectrum of previous corneal surgery. *J Refract Surg*. 2018;34(10):654–63.
17. Guber I, Mouvet V, Bergin C, Perritaz S, Othenin-Girard P, Majo F. Clinical outcomes and cataract formation rates in eyes 10 years after posterior phakic lens implantation for myopia. *JAMA Ophthalmol*. 2016;134(5):487–94.
18. Nakamura T, Isogai N, Kojima T, Yoshida Y, Sugiyama Y. Posterior chamber phakic intraocular lens implantation for the correction of myopia and myopic astigmatism: a retrospective 10-year follow-up study. *Am J Ophthalmol*. 2019;206:1–10.
19. Sanders DR. Anterior subcapsular opacities and cataracts 5 years after surgery in the Visian implantable collamer lens FDA trial. *J Refract Surg*. 2008;24(6):566–70.
20. Gonvers M, Bornet C, Othenin-Girard P. Implantable contact lens for moderate to high myopia: relationship of vaulting to cataract formation. *J Cataract Refract Surg*. 2003;29(5):918–24.
21. Shimizu K, Kamiya K, Igarashi A, Shiratani T. Early clinical outcomes of implantation of posterior chamber phakic intraocular lens with a central hole (Hole ICL) for moderate to high myopia. *Br J Ophthalmol*. 2012;96(3):409–12.
22. Fernández-Vigo JI, Macarro-Merino A, Fernández-Francos J, De-Pablo-Gómez-de-Liaño L, Martínez-de-la-Casa JM, García-Feijóo J, et al. Computational study of aqueous humor dynamics assessing the vault and the pupil diameter in two posterior-chamber phakic lenses. *Invest Ophthalmol Vis Sci*. 2016;57(11):4625–31.
23. Kawamorita T, Shimizu K, Shoji N. Effect of hole size on fluid dynamics of a posterior-chamber phakic intraocular lens with a central perforation by using computational fluid dynamics. *Graefes Arch Clin Exp Ophthalmol*. 2016;254(4):739–44.
24. Montés-Micó R, Ruiz-Mesa R, Rodríguez-Prats JL, Tañá-Rivero P. Posterior-chamber phakic implantable collamer lenses with a central port: a review. *Acta Ophthalmol*. 2021;99(3):e288–301.
25. Anwar M. Dissection technique in lamellar keratoplasty. *Br J Ophthalmol*. 1972;56(9):711–3.
26. Alfonso JF, Lisa C, Fernández-Vega Cueto L, Belda-Salmerón L, Madrid-Costa D, Montés-Micó R. Clinical outcomes after implantation of a posterior chamber collagen copolymer phakic intraocular lens with a central hole for myopic correction. *J Cataract Refract Surg*. 2013;39(6):915–21.
27. Fernández-Vega-Cueto L, Alfonso-Bartolozzi B, Lisa C, Madrid-Costa D, Alfonso JF. Seven-year follow-up of posterior chamber phakic intraocular lens with central port design. *Eye Vis (Lond)*. 2021;8(1):23.
28. Leccisotti A. Photorefractive keratectomy with mitomycin C after deep anterior lamellar keratoplasty for keratoconus. *Cornea*. 2008;27(4):417–20.
29. Sorkin N, Einan-Lifshitz A, Abelson S, Boutin T, Showail M, Borovik A, et al. Stepwise guided photorefractive keratectomy in treatment of irregular astigmatism after penetrating keratoplasty and deep anterior lamellar keratoplasty. *Cornea*. 2017;36(11):1308–15.
30. Acar BT, Utine CA, Acar S, Ciftci F. Laser in situ keratomileusis to manage refractive errors after deep anterior lamellar keratoplasty. *J Cataract Refract Surg*. 2012;38(6):1020–7.
31. Balestrazzi A, Balestrazzi A, Menicacci F, Cartocci G, Menicacci F, Michieletto P, et al. Femtosecond laser-assisted in situ keratomileusis for the correction of residual ametropia after deep anterior lamellar keratoplasty: a pilot investigation. *Eye (Lond)*. 2017;31(8):1168–75.
32. Alfonso JF, Lisa C, Fernández-Vega L, Madrid-Costa D, Poo-López A, Montés-Micó R. Intrastromal corneal ring segments and posterior chamber phakic intraocular lens implantation for keratoconus correction. *J Cataract Refract Surg*. 2011;37(4):706–13.
33. Fernandes P, González-Méijome JM, Madrid-Costa D, Ferrer-Blasco T, Jorge J, Montés-Micó R. Implantable collamer posterior chamber intraocular lenses: a review of potential complications. *J Refract Surg*. 2011;27(10):765–76.
34. Rodríguez-Una I, Rodríguez-Calvo PP, Fernández-Vega Cueto L, Lisa C, Fernández-Vega Cueto A, Alfonso JF. Intraocular pressure after implantation of a phakic collamer intraocular lens with a central hole. *J Refract Surg*. 2017;33(4):244–9.
35. Gonzalez-Lopez F, Bouza-Miguens C, Tejerina V, Mompean B, Ortega-Usobiaga J, Bilbao-Calabuig R. Long-term assessment of crystalline lens transparency in eyes implanted with a central-hole phakic collamer lens developing low postoperative vault. *J Cataract Refract Surg*. 2021;47(2):204–10.
36. Yang W, Zhao J, Sun L, Zhao J, Niu L, Wang X, et al. Four-year observation of the changes in corneal endothelium cell density and correlated factors after Implantable Collamer Lens V4c implantation. *Br J Ophthalmol*. 2021;105(5):625–30.

Ready to submit your research? Choose BMC and benefit from:

- fast, convenient online submission
- thorough peer review by experienced researchers in your field
- rapid publication on acceptance
- support for research data, including large and complex data types
- gold Open Access which fosters wider collaboration and increased citations
- maximum visibility for your research: over 100M website views per year

At BMC, research is always in progress.

Learn more biomedcentral.com/submissions

